



PRESENTING CLINICAL SIGNS

History: Elevated NT-proBNP. Excessive panting. Receiving sotalol 27 mg BID.

DATE

9/2/21

ECHOCARDIOGRAPHIC FINDINGS

2D, M-mode, and Doppler study.

PERFORMED BY:

Jenn

Left atrial size is normal. The mitral valve is normal. Left ventricular wall thickness is normal. Left ventricular internal dimensions are normal. Left ventricular systolic function is hyperdynamic. The aorta and aortic valve appear normal, though there is very mildly increased velocity laminar flow in the ascending aorta. Right atrial and right ventricular dimensions are normal. The tricuspid valve is normal. The pulmonary artery and pulmonic valve are normal. No shunting lesions are visualized. No pericardial effusion or cardiac masses are seen.

INTERPRETED BY

Keith Blass, DVM,
MS, DACVIM
(Cardiology)

LA - 36.2 mm
IVSd - 8.1 mm
LVPWd - 8.8 mm
LVIDd - 36.9 mm
LVIDs - 23.6 mm
FS - 36%
RA - 25.1 mm
LVOT - 1.58 m/s
RVOT - 0.89 m/s

PATIENT

Skye Graham

SPECIES

Canine

ASSESSMENT/RECOMMENDATIONS

Normal echocardiogram

BREED

Great Pyrenees Mix

This examination demonstrates no evidence of structural heart disease. As such, no reason for Skye's elevated BNP level is appreciated in the image set, though if she does have an arrhythmia present, the arrhythmia could be the cause of the elevation.

Skye does have very mildly increased flow velocity in her aorta, which could potentially result in the auscultation of a functional/innocent left basilar systolic murmur.

SEX

FS

No therapy is recommended based on this exam. Continued use of sotalol should be based on the results of Skye's Holter monitor.

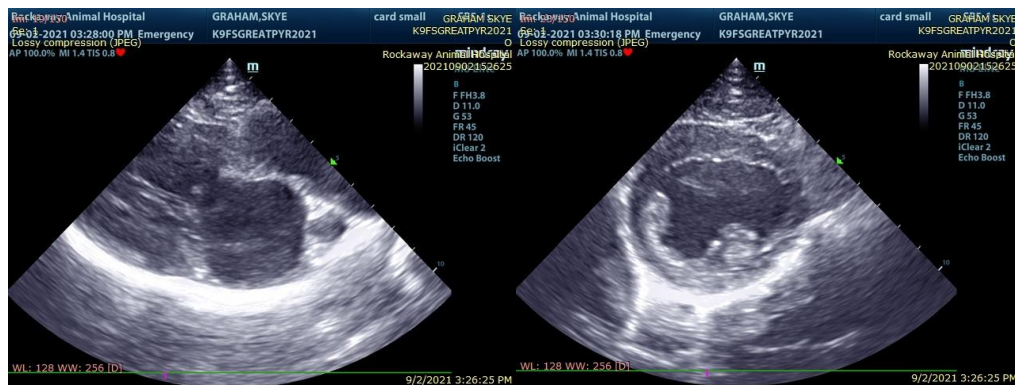
AGE

5 mo

A recheck echocardiogram is recommended if new physical exam and/or clinical abnormalities suggestive of cardiac dysfunction develop.

WEIGHT

57 lb



HOSPITAL NAME

Rockaway AH

REFERRING VET

Dr. Maniar



DATE

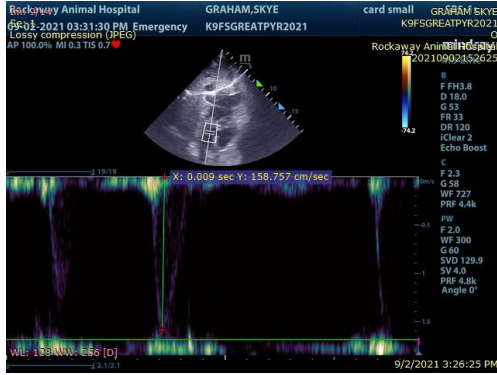
9/2/21

PERFORMED BY:

Jenn

INTERPRETED BY

Keith Blass, DVM,
MS, DACVIM
(Cardiology)



The information and recommendations provided are based on the images presented by the referring veterinarian. No evaluation can be communicated regarding pathology that was not visible in the image/video clips provided.

Thank you for this referral. If the clinical or image interpretation does not parallel your findings or if I can be of any further assistance please contact me.

PATIENT

Skye Graham

Keith Blass, DVM, MS, DACVIM (Cardiology)
KeithBlass@gmail.com
631-804-5754

SPECIES

Canine

BREED

Great Pyrenees Mix

SEX

FS

AGE

5 mo

WEIGHT

57 lb

HOSPITAL NAME

Rockaway AH

REFERRING VET

Dr. Maniar